Indications

- Unsure dates
- Large for gestational age (LGA) or small for gestational age (SGA)
- Maternal symptoms, such as bleeding or pain, to rule out ectopic pregnancy, threatened abortion, ovarian torsion, hemorrhagic corpus luteum or molar pregnancy
- Intrauterine contraceptive device localization
- Adjunct to chorionic villus sampling

Equipment

- Vaginal probe/transducer with a frequency of 7 MHz or higher
- Abdominal probe/transducer of 5 MHz or higher
- M-mode capabilities to document viability and heart rate
- Color flow imaging (CFI) or Philips Color Power Angio (CPA) imaging

Anatomy

Embryonic

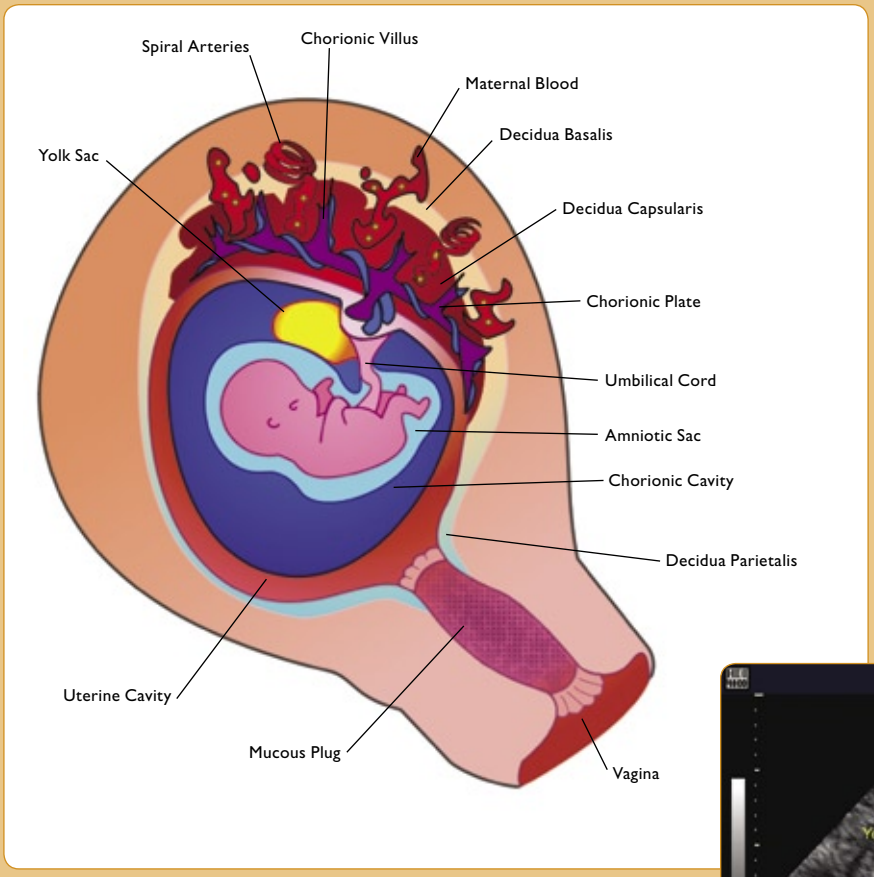

Maternal

- Uterine shape or masses
- Corpus luteum and potential adnexal masses

Sonographic Signs by Week

	Week 4	Week 5	Week 6	Week 7	Week8	Week 9	Week 10	Week 11
Sonolucent fundal sac								
Corpus luteum	1-10 cm without septations							
Yolk sac			4-6 mm					
Gestational sac			Measure on three planes – 1 mm growth per day					
Crown Rump Length (CRL)								
Heart flutter			100-175 bpm					
Amnion chorion separation			Vaginal scan					
					Abdominal scan			
Rhombencephalon								
Head larger than body								
Parallel neural tube								
Arm and leg buds								
Midgut herniation					Echogenic mass at base of umbilical cord			
Choroid plexus						Echogenic filling of ventricles		
Cerebral falx and cranial midline								
Urine in bladder								
Fingers and toes								Vaginal scan

Exam Documentation

- Crown-rump length
- Average gestational sac size using measurements from three orthogonal dimensions
- Fetal heart rate
- Number of embryos/sacs
- Bilateral ovaries
- Cervix
- Uterus
- Cornea of the uterus and fallopian tubes
- Posterior cul-de-sac
- Morison's pouch in the presence of free fluid in the pelvis
- CFI or CPA of flow to suspicious masses

Pregnancy Failure

- A complete abortion (CAB) images with a uterus devoid of embryonic tissue
- Retained products of conception (RPOC) is the result of an incomplete or missed abortion (MAB).
- A gravid patient with bleeding poses a threatened abortion (TAB) and scanning may reveal a viable embryo. About 50% of the cases result in a CAB.
- A large yolk sac (>7 mm) or irregular shaped gestational sac lacking fetal parts raises suspicion for an anembryonic pregnancy (blighted ovum).

Ectopic Pregnancy

- Any pregnancy located outside the fundal portion of the uterus.
- The ampulla is the most common area for abnormal implantation.
- Uterus lacks normal double decidual reaction, but a teardrop-shaped pocket of fluid may image in the endometrium.
- Free fluid in pelvis representing blood.
- Complex mass in adnexa or cul-de-sac may represent ruptured ectopic pregnancy.
- Coexisting extrauterine and intrauterine pregnancy (heterotopic).