# ARTICLES

# *Increasing the Detection Rate of Normal Fetal Cardiac Structures*
## *A Real-Time Approach*

TED SCOTT, MAppSc, RDMS, RDCS, RVT[*]

HANS SWAN, PhD[†]

GERALD MORAN, PhD[‡]

TAPAS MONDAL, MD[§]

JUDY JONES, BSc, RDMS, RDCS[||]

KARM GURAM, MD[‡]

JAIME HUFF, BSc, RDCS[||]

The purpose of this study was to determine if acquiring real-time sweeps of the fetal heart would be a more effective method of identifying normal cardiac structures compared with using static images during routine second-trimester obstetric sonograms. Subjects were scanned using three different techniques. The static image acquisition (protocol A) included three images of the fetal heart. Protocol B used two gray-scale sweeps through the fetal heart. Protocol C acquired three color loops of the fetal heart. The sweeps demonstrated a complete normal cardiac assessment in 71% of studies, compared with the static image and color Doppler techniques that completed a normal cardiac assessment in only 39% of studies, respectively. The real-time technique detected four chambers, the left ventricular outflow tract (LVOT), the right ventricular outflow tract (RVOT), the LVOT/RVOT crossover, and size and axis of the heart with a greater frequency than the static images and color loops in all cases. In addition, the real-time technique was able to demonstrate the pulmonary veins in 56% of cases compared with 3.6% for static images. The color Doppler acquisition demonstrated blood flow through the atrial-ventricular and semilunar valves in 86% of cases.

*Key words:* sonography, fetal heart, real-time, static, detection, tissue harmonic

From [*]Mohawk-McMaster Institute for Applied Health Sciences, Hamilton, Ontario, Canada; [†]Charles Sturt University, Wagga Wagga, NSW, Australia; [‡]McMaster University, Hamilton, Ontario, Canada; [§]McMaster Children's Hospital, Hamilton, Ontario, Canada; [||]London Health Sciences, London, Ontario, Canada.

Correspondence: Ted Scott, MAppSc, RDMS, RDCS, RVT, 1400 Main Street West, Hamilton, Ontario, Canada L8S 1C7. E-mail: ted.scott@mohawkcollege.ca.

DOI: 10.1177/8756479308315234

The use of sonographic imaging for routine fetal screening in the second trimester has been adopted by the Canadian health care system and a number of European countries as a standard of care.[1] According to a survey of 2758 referrals to the fetal cardiology unit at Guy's Hospital,

London, UK, the low-risk population for congenital heart defects is the source of 80% of congenital heart defects.[2] This fact underscores the importance of routine screening for detecting congenital heart defects. Routine screening provides a more accurate measure of gestational age and earlier detection of multiple pregnancies, and it may detect congenital malformations. The Eurofetus study identified marked differences in sensitivity for the detection of different malformations. Abnormalities of the urinary system and nervous system were most easily detected with a sensitivity of 88.5% and 88.3%, respectively.[1] In this study, cardiac abnormalities were not well detected; sensitivity for major cardiac defects was 38.8% and minor defects 20.8%.[1] In Canada, an obstetric screening examination is performed in real time and documented as a series of still images archived electronically or on film. The interpretation of the cardiac images is performed by a radiologist or obstetrician using the still images. Present detection rates for congenital heart defects (CHD) vary widely depending on a number of factors: operator skills, maternal obesity, fetal position, inadequate image optimization, and visualization of the four-chamber view only.[3] The American College of Radiology (ACR) and the International Society of Ultrasound in Obstetrics & Gynecology (ISUOG) have published guidelines for routine second-trimester screening that require the four-chamber view and, where possible, views of the left ventricular outflow tract (LVOT) and right ventricular outflow tract (RVOT) to address this limitation.[4,5]

Acquisition of static images of the fetal heart provides a very limited quantity of diagnostic information; the identification of normal cardiac structures cannot be completely demonstrated as a series of a few static slice images. The interpretation of key structural relationships can be completed only during a real-time interrogation. In practice, the detection of the critical normal structures is accomplished solely by the sonographer. This approach limits the interpreter's ability to confirm the findings of the sonographer. The main objective of this pilot study is to demonstrate that acquiring real-time loops of the fetal heart can be accomplished with minimal additional acquisition time and skill. In addition, the static and real-time techniques are compared in an effort to demonstrate the additional anatomical information that is accessible using a real-time acquisition.

The real-time loops will add considerable diagnostic value to the screening process because two interpretations will be performed on every examination: the preliminary review by the sonographer and the summary review by the sonologist. Another advantage of using the real-time loops is the opportunity it provides the sonologist to review the images repeatedly in real time and evaluate structures at different points during the cardiac cycle. The ability to assess structures during the diastolic phase has been found by Chaoui[6] to be helpful in detecting atrial-ventricular septal defects. Furthermore, it is well established that observation of moving structures provides a more sensitive means of detecting small differences in form.[7] A cine loop of a sweep through the cardiac outflow tracts will allow the sonologist to better appreciate the relationship between the LVOT and RVOT, which is crucial for ruling out conotruncal abnormalities. Hosono et al[8] found the use of tissue harmonic imaging (THI) to be advantageous in imaging fetal cardiac tumors because of improvements in image contrast. Using THI will improve the quality of the images and may influence the detection rate of cardiac structures as well.

Acquisition of real-time loops assumes that the sonography systems that are used are capable of storing and transmitting real-time loops to a network. A survey of 21 local screening centers illustrated in Table 1 found that 95% of centers acquired and stored images electronically using a Picture Archiving Communications System (PACS). Most centers acquired three static images of the fetal heart: the four-chamber view and the LVOT and RVOT view (see Table 1). For the purpose of this pilot study, this combination of static images represents the conventional technique, protocol A.

## Research Question/Objectives

This study compared static and real-time imaging techniques applied to the assessment of the fetal heart in routine screening.

**TABLE 1.**
**Clinical Site Survey Data**

| Second-Trimester Obstetrical Examinations/Day | Number (%) of Sites | Routine Views | Number (%) | Operating PACS (%) |
|---|---|---|---|---|
| 0–5 | 7 (33) | Four chamber | 21 (100) | 20 (95) |
| 5–10 | 9 (42) | LVOT | 18 (86) | |
| 10–15 | 2 (10) | RVOT | 18 (86) | |
| 15–25 | 1 (5) | Aortic arch (long axis) | 7 (33) | |
| 25–30 | 1 (5) | Ductal arch (long axis) | 3 (14) | |
| 30–35 | | Great vessels (short axis) | 6 (29) | |
| >35 | 1 (5) | Septum | 1 (5) | |

LVOT, left ventricular outflow tract; RVOT, right ventricular outflow tract; PACS, Picture Archiving Communications System.

**RESEARCH AIMS**

- Demonstrate the ability to acquire the experimental protocol B in less than five minutes
- Demonstrate an increased rate of detection of cardiac structures using real-time compared with static images

## *Method*

The research protocol was reviewed and approved for use by the ethics committee of Charles Sturt University (Wagga Wagga, NSW, Australia) and the ethics committee of Mohawk College (Hamilton, Ontario, Canada). Exclusion criteria included a family history of congenital heart defects or an abnormal second-trimester obstetric sonogram. All 28 subjects had a normal second-trimester sonogram prior to participation in this study. Images were acquired using the Philips Medical Systems (Bothell, Washington) HDI 5000 and Envisor sonography systems. Images were acquired using a curvilinear array transducer with a fetal cardiac preset using tissue harmonic image processing.

Subjects were scanned using three different techniques. The static image acquisition, protocol A, acquired three images of the fetal heart: the four chamber view, the LVOT view, and the RVOT view (see Figures 1–3). The real-time sweep, protocol B, acquired two gray-scale sweeps of four seconds' duration each through the fetal heart. The first sweep began at the level of the transverse abdominal circumference with a visible stomach and swept into the transverse four-chamber view. The second sweep began at the four-chamber view and swept through the LVOT and RVOT (see Figures 4–7). Using protocol C, three real-time color cine loops of four seconds' duration were

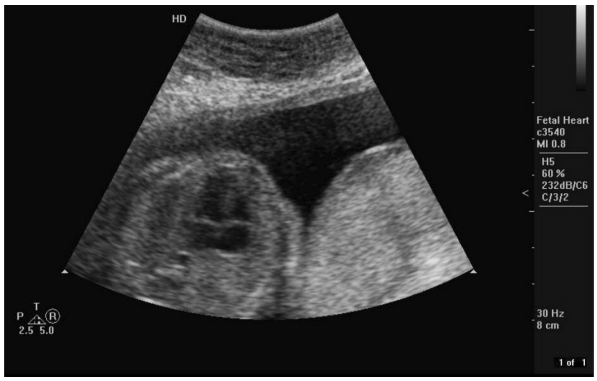


**FIGURE 1.** Static image of the four-chamber view.

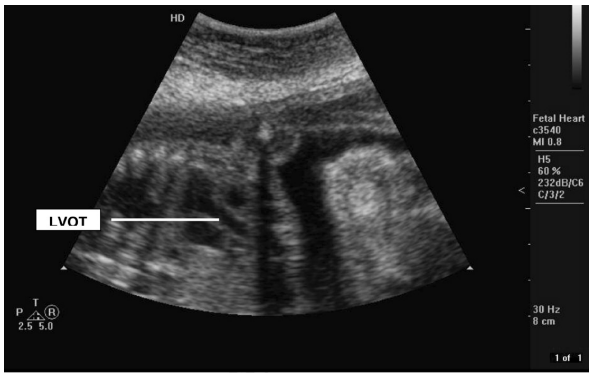


**FIGURE 2.** Static image of the left ventricular outflow tract (LVOT) view.

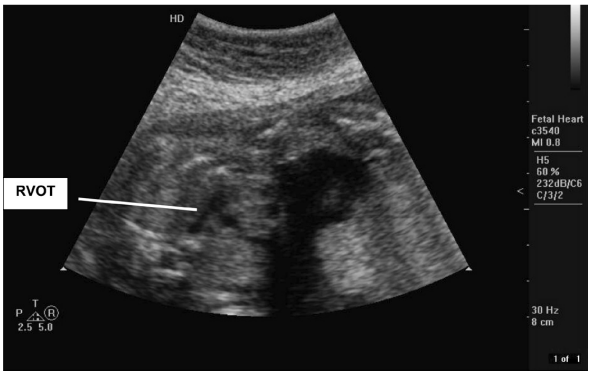


**FIGURE 3.** Static image of the right ventricular outflow tract (RVOT) view.

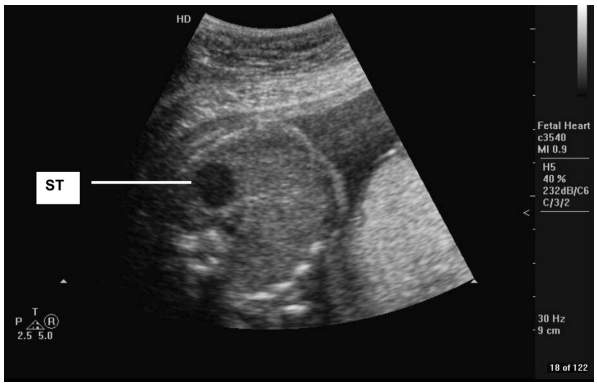


**FIGURE 4.** Abdominal circumference from real-time sweep 1.

**FIGURE 5.** Four-chamber view from real-time sweep 1.

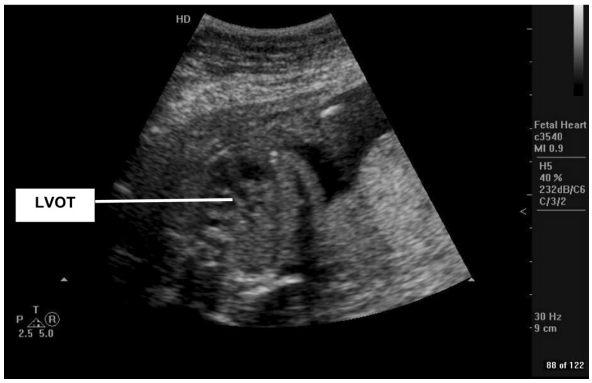


**FIGURE 6.** Left ventricular outflow tract (LVOT) view from real-time sweep 2.

acquired. The first was a sweep from the level of the transverse abdominal circumference with a visible stomach into the transverse four-chamber view. The second sweep began at the four-chamber view and swept through the LVOT and RVOT. The third was a color cine loop of the three-vessel view.

Informed consent was obtained, and then subjects were randomly assigned a sonographer who completed protocol A, B, or C. Five sonographers acquired images for this project. All sonographers had a minimum of three years' experience in obstetrical sonography and were credentialed as RDMS (obstetrics and gynecology) by the American Registry of Diagnostic Medical Sonographers (ARDMS). The sonographer recorded the scan time for the acquisition using an electronic timer. Every subject was scanned by at least two different sonographers. Images were acquired and stored on the Philips Medical Systems Xcelera Minipacs. No additional training was provided to save the real-time loops compared with the static images. Sonographers were limited to a maximum of ten minutes to complete each protocol in an effort to replicate the practical limitations of the clinical environment.

The image sequences acquired were reviewed independently by two different fetal cardiac sonography experts blinded to each other's results. The reviewers are experts in acquiring and interpreting fetal cardiac sonograms. The first was a sonographer (JJ) with 16 years of pediatric cardiac experience registered with RDCS (pediatric and fetal echo) credentials, and the second was a pediatric cardiologist (TM). In addition to the expert reviewers, two nonexperts reviewed the images independently and were blinded to each other's results. The first was a radiology resident in year three of his training (KG), and the second was a cardiac

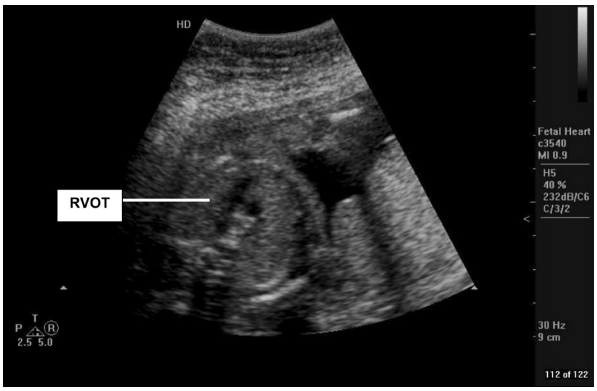


**FIGURE 7.** Right ventricular outflow tract (RVOT) view from real-time sweep 2.

**TABLE 2.**
**Subject Characteristics and Protocol Acquisition Times**

| Subjects (N = 28) | Average | 95% Confidence Interval |
|---|---|---|
| Gestational age | 27 weeks 0 days | 24 weeks, 5 days to 28 weeks, 6 days |
| Maternal body mass index | 27.8 | 25.8–29.8 |
| Maternal body wall, cm | 1.8 | 1.6–1.9 |
| Acquisition time, protocol A (00:00) | 3:49 | 2:39–4:58 |
| Acquisition time, protocol B (00:00) | 4:18 | 3:19–5:17 |
| Acquisition time, protocol C (00:00) | 6:32 | 5:14–7:51 |

sonographer (JH) with RDCS credentials and less than one year of experience in performing fetal cardiac studies. Each observer recorded the detection of five cardiac structures as detected = 1 or missed = 0 (see Table 3). A complete normal assessment requires a score of 5, and an incomplete assessment is recorded as any total less than 5.

### STATISTICAL ANALYSIS

Interobserver differences were tested using a kappa score for agreement between detection of structures. A one-way analysis of variance (ANOVA) was performed to test for agreement between the means of total detection rate scores and the means of the acquisition times. Detection rate differences for complete and incomplete assessments were analyzed using the McNemar chi-square test.

## Results

The subjects average gestational age was 27 weeks, 0 days, with an average body mass index (BMI) of 27.8 and an average body wall thickness of 1.8 cm (see Table 2). The acquisition time for the static images (protocol A) is statistically equivalent to the acquisition time for protocol B, and the mean time for both was less than five minutes (see Table 2). The acquisition of protocol C exceeded five minutes, with a mean time of 6:32, which is statistically different from protocols A and B. Interobserver agreement for the detection of cardiac structures using static images ranged from fair to excellent using kappa scores. Interobserver agreement for the detection of cardiac structures using real-time images ranged from excellent to poor using kappa scores.

### DETECTION RATES

The real-time image loops were found to have the highest detection rates for all anatomic structures compared with the static images and color loops (see Table 3). The four-chamber view was identified in 100% of all real-time loops and in only 68% of static images and 84% of color loops. The LVOT and RVOT crossover was detected in 73% of real-time loops and only 47% of static images. Similar differences were found for the LVOT and RVOT as individual structures.

Using the static images, 39% of studies generated a score of 5 for complete assessment compared with the real-time technique, which was able to completely assess the normal structures in 71% of studies. This generated a statistically significant difference between proportions of 0.321 ($P$ = .0352) using the McNemar chi-square test.

The color Doppler loops provided a complete assessment in only 39% of cases. The color Doppler loops did provide the ability to assess the blood flow through the atrial-ventricular valves and semilunar valves in most cases, and this represents additional diagnostic information compared

**TABLE 3.**
**Rate of Detection of Cardiac Structures by Technique (in Percentages)**

| Expert (N = 28) | Four Chamber | LVOT | RVOT | RVOT/LVOT Crossover | Axis and Size | Complete Examination |
|---|---|---|---|---|---|---|
| Static | 68 | 64 | 64 | 47 | 93 | 39 |
| Color Doppler loops | 84 | 82 | 79 | 73 | 93 | 39 |
| Gray-scale loops | 100 | 86 | 81 | 73 | 100 | 71 |

LVOT, left ventricular outflow tract; RVOT, right ventricular outflow tract.

**TABLE 4.**
**Detection Rate of Color Flow Using Color Doppler Loops by View (in Percentages)**

| Expert (N = 28) | Four Chamber | Five Chamber | Three-Vessel View | Assessment of Valves for Regurgitation |
|---|---|---|---|---|
| Color Doppler loops | 91 | 84 | 45 | 86 |

**TABLE 5.**
**Detection Rate Differences Between Experts and Nonexperts (in Percentages)**

| Expert/Nonexpert Difference | Four Chamber | LVOT | RVOT | RVOT/LVOT Crossover | Axis and Size | Complete Examination |
|---|---|---|---|---|---|---|
| Static | 0 | 13 | 4 | 8 | 7 | 5 |
| Color Doppler loops | 11 | 4 | 0 | 7 | 2 | 28 |
| Gray-scale loops | 14 | 4 | 3 | 5 | 2 | 15 |

LVOT, left ventricular outflow tract; RVOT, right ventricular outflow tract.

with the gray-scale static and real-time loops. The color Doppler loops were able to assess the four-chamber view and five-chamber view in most cases. The three-vessel view was achieved only in 45% of cases (see Table 4).

## EXPERT/NONEXPERT DIFFERENCES

The expert reviewers and nonexpert reviewers agreed closely in their assessment of static images. The largest difference between these groups was in the evaluation of the LVOT, with a difference of 13% between groups (see Table 5). All other structures differed by less than 10%, respectively. There was close agreement between the experts and nonexperts interpreting the gray-scale and color loops, with the exception of the four-chamber view, in which the gray-scale loop differed by 14% and the color loop differed by 11%. Assessment of a complete examination was in close agreement between experts and nonexperts for the static images, with a greater difference of 15% and 28% (see Table 5) with the gray-scale and color loops, respectively.

## SAMPLE IMAGES

The static image of the four-chamber view allows the observer to distinguish the axis, size, and left/right chambers under ideal conditions (see Figure 1). The static images of the LVOT and RVOT (see Figures 2 and 3) will describe continuity between the outflow tracts and the corresponding chambers under ideal conditions. The static images cannot effectively assess the cardiac valves or cardiac motion.

Static images have been extracted from the real-time loops in an attempt to demonstrate the added value that loops provide. The first sweep begins at the transverse abdominal circumference (see Figure 4). The four-chamber view is visualized next in Figure 5. The second sweep demonstrates

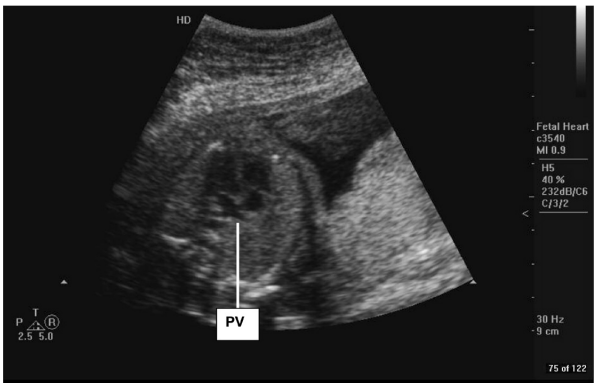


**FIGURE 8.** Pulmonary veins (PV) from real-time sweep 2.

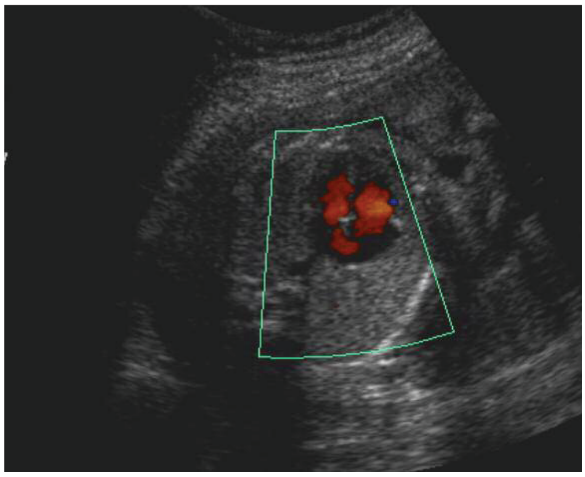

**FIGURE 9.** Four-chamber view with color Doppler from sweep 1.

the LVOT in Figure 6, and the RVOT is visualized in Figure 7. In addition, the real-time sweeps provided continuity between the stomach and abdominal circumference in 100% of real-time studies. One or more pulmonary veins were visualized as contiguous structures with the left atrium in 56% of real-time cases compared with 3.6% of cases with static images (see Figure 8). A color image extracted from a sweep from the abdominal circumference to the four-chamber view demonstrated blood flow through the atrial-ventricular valves in Figure 9. The blood flow through the LVOT is evident (see Figure 10) as an image acquired during the sweep from the four-chamber through the outflow tracts. In Figure 11, the great vessels demonstrate antegrade blood flow in a three-vessel view.

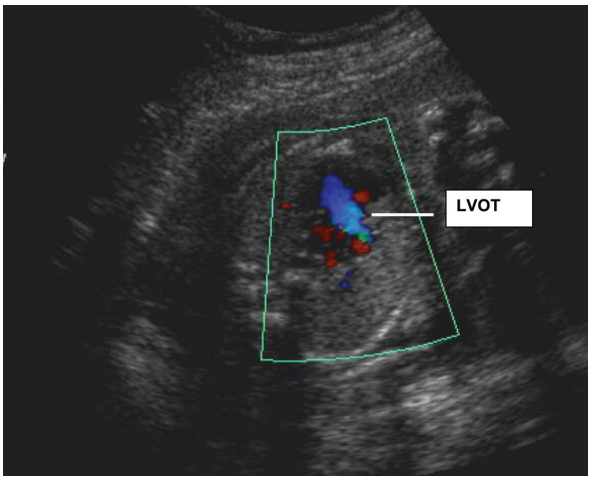


**FIGURE 10.** Five-chamber view with color Doppler from sweep 2. LVOT, left ventricular outflow tract.

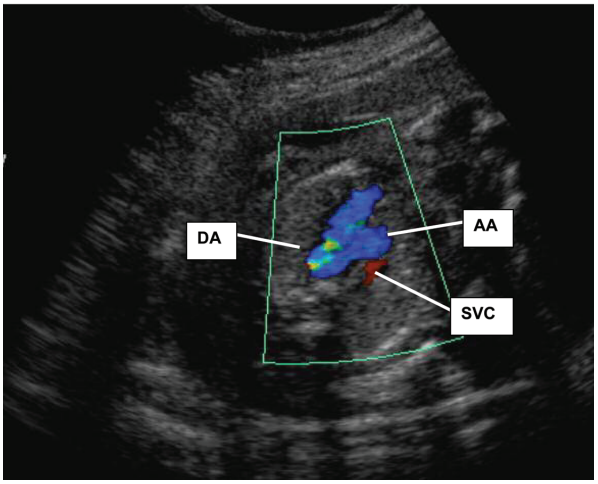


**FIGURE 11.** Three-vessel view from color Doppler cine loop 3. AA, ascending aorta; DA, descending aorta; SVC, superior vena cava.

## Discussion

The subjects were a representative sample of expectant mothers in the late second and early third trimesters. The requirement of a normal diagnostic second-trimester sonogram result as a prerequisite for participation in this study resulted in the mean gestational age of 27 weeks, 0 days. The gray-scale, real-time sweeps were acquired as quickly as the static images, and very little additional expertise was required to capture the real-time loops.

The structure of the heart is complex, and relationships and continuity between structures such as the crossover of the outflow tracts are critical for determining normalcy. Three static views of the four-chamber and outflow tracts are inadequate for complete assessment in most cases. Static images are much less likely to be able to demonstrate subtle anatomic structures such as the moderator band and atrioventricular valve offset, which are useful for distinguishing the left and right chambers. Static images cannot assess the valves and their motion effectively, and this limits observer confidence in detecting the outflow tracts and their relationship. The real-time loops are able to detect these subtle anatomic structures and their motion; this fact is reflected in the ability of the real-time loops to detect a complete normal heart in 71% of studies compared with 39% of static studies. In addition to the identification of the four-chamber and outflow tracts, the real-time sweeps provided the continuity of the left-sided stomach in the abdomen as the sweep translates from the abdomen to the chest in 100% of cases.

In a few cases, the relationship between the outflow tracts could not be established in static images or real time at normal speed, but using a frame-by-frame analysis, we were able to establish that relationship. This affirms the value of acquiring loops of information rather than individual slices as well as the need to reevaluate the heart in real time after the image acquisition process.

The color Doppler loops provided useful blood flow information in most cases, but this advantage was limited to some degree by the fact that color blooming had the effect of obscuring part of the anatomy represented in gray scale. Unfortunately, our PACS and sonography systems did not permit the suppression of color. Another drawback to the color Doppler was the need for additional operator expertise to fine-tune the color velocity scale or pulse repetition frequency (PRF) and color gain. The three-vessel view was detected in only 45% of cases compared with 91% and 84% of cases for the four-chamber and five-chamber views, respectively. This difference most likely reflects the relative difficulty in acquiring the three-vessel view compared with the four-chamber and five-chamber views.

It is interesting to note that in nearly all cases, there were only minor differences in the detection rates between the expert image reviewers and nonexpert reviewers. Review of the static images resulted in the least difference between these groups, likely due to the fact that reviewers assessed only one image/view in comparison with the real-time loops that generated a series of 120 images from a four-second acquisition. The cine loops provided the reviewers with so much additional information that it had the effect of introducing a wider range of interpretation. On the basis of these findings, it is clear that the identification of the four chambers, outflow tracts, outflow tract crossover, situs, and location can be achieved consistently by experts and nonexperts.

## REAL-TIME METHODOLOGY

Typically, second-trimester screening examinations are scheduled for approximately 30 minutes, in which time the sonographer is obliged to interrogate the maternal pelvic and fetal anatomy, as well as acquire representative images and measurements to estimate gestational age. Fetal cardiac anatomy, owing to its complex shape and rapid movement, represents the sonographer's greatest diagnostic challenge compared with static fetal anatomical structures such as the brain or abdominal organs. Given these constraints, a robust screening technique needs to be able to provide the maximum relevant anatomical information with the minimum operator skill and time. For most screening centers, a reasonable goal would be to identify an abnormal heart and refer the patient to a pediatric cardiology laboratory to diagnose the specific nature of the defect. The use of color Doppler cine loops did provide additional blood flow information in most cases, but this advantage was offset by the additional time required to acquire these loops, the additional operator skill that is needed to apply color Doppler effectively, and the fact that the color may obscure visualization of some gray-scale anatomy unless it is suppressed. For these reasons, it is proposed that the two-sweep cine loop acquisition technique tested in this study be used for assessing the fetal heart in the second trimester. Applying this method of acquisition

will allow the image interpreter to identify the key cardiac anatomical landmarks and relationships that were assessed in this study in most cases. This method will provide the most effective assessment of fetal cardiac anatomy with minimal additional time and skill.

### STUDY LIMITATIONS

It was not possible to blind the observer to the techniques used for acquisition because a static image is inherently different from a real-time loop. The manipulation of the real-time loops as a frame-by-frame analysis was left to the discretion of the individual reviewers. Although this may have limited the standardization of the image presentation, the manipulation of frame rate by the user is a key advantage of the technique.

## Conclusion

Real-time sweeps through the fetal heart are easily and rapidly acquired with minimal additional operator skill. Acquiring four-second, real-time loops provides the sonologist with the information required to more effectively assess the fetal heart. Real-time sweep acquisitions of fetal cardiac structures are much more effective in completing a normal assessment. This study was able to demonstrate a complete cardiac assessment in 71% of studies using a real-time acquisition technique compared with 39% of static image acquisitions. The use of color Doppler provided blood flow information of the atrial-ventricular valves in 86% of subjects. A standardized two-sweep acquisition through the fetal heart can be acquired quickly and with minimal additional operator skill. In the future, studies comparing the performance of this technique between normal and abnormal fetal hearts will be needed to demonstrate the clinical value of real-time loops for detecting congenital heart disease.

## Acknowledgments

This project was undertaken with the financial support of the SDMS Education Foundation, Graduate Research Award, and the Bracco Diagnostics Research Award. Thanks are given to the following sonographers: Malka Glasner, Mandie Bird, Rob Noftle, and Melissa Wood for their efforts in acquiring the fetal cardiac images. The authors also thank Philips Medical Systems, Canada, and Mohawk College for their support of this project. Equipment was provided by Philips Medical Systems, Canada, and laboratory space was allotted by Diane Barrafato, associate dean, Medical Radiation Sciences, School of Health Sciences, Mohawk College.

## References

1. Johnson J: Overview of obstetric sonography, in Rumack C, Wilson S, Charboneau J (eds): *Diagnostic Ultrasound*. 3rd ed. St. Louis, MO, Elsevier Mosby, 2005, pp 1039–1059.
2. Sharland G: Routine fetal cardiac screening: what are we doing and what should we do? *Prenat Diagn* 2004;24: 1123–1129.
3. Wong S, Chan F, Cincotta R, Lee-Tannock A, Ward C: Factors influencing the prenatal detection of structural heart diseases. *Ultrasound Obstet Gynecol* 2003;21:19–25.
4. ACR: ACR practice guideline for the performance of antepartum obstetrical ultrasound. *Antepartum Obstet Ultrasound* 2003;781–787.
5. ISUOG Education Committee: Cardiac screening of the fetus: guidelines for performing the 'basic' and 'extended basic' cardiac scan. *Ultrasound Obstet Gynecol* 2006;27:107–113.
6. Chaoui R: The four chamber view: four reasons why it seems to fail in screening for cardiac abnormalities and suggestions to improve detection rate. *Ultrasound Obstet Gynecol* 2003;22:3–10.
7. Ivry R, Cohen A: Asymmetry in visual search for targets defined by differences in movement speed. *J Exp Psychol* 1992;18:1045–1057.
8. Hosono T, Chiba Y, Kanai H, Kanagawa T: Initial experiences of tissue harmonic imaging in the diagnosis of fetal cardiac tumors. *Ultrasound Obstet Gynecol* 2002;19:400–402.